

## RESEARCH ARTICLE

# Retinal arteriolar parameters as a surrogate marker of intracranial vascular pathology

Ahmed Abdelhak<sup>1</sup>  | Isaac Solomon<sup>2</sup> | Shivany Condor Montes<sup>1</sup> | Alexandra Saias<sup>1</sup> | Christian Cordano<sup>1</sup> | Breton Asken<sup>1</sup> | Corrina Fonseca<sup>1</sup> | Frederike Cosima Oertel<sup>1</sup> | Konstantinos Arfanakis<sup>3,4</sup> | Adam M. Staffaroni<sup>1</sup> | Joel H. Kramer<sup>1</sup> | Michael Geschwind<sup>1</sup> | Bruce L. Miller<sup>1</sup> | Fanny M. Elahi<sup>1,5,#</sup> | Ari J. Green<sup>1,6,#</sup>

<sup>1</sup>Weill Institute for Neurosciences, Department of Neurology, University of California at San Francisco (UCSF), San Francisco, California, USA

<sup>2</sup>San Diego School of Medicine, University of California, San Diego, La Jolla, California, USA

<sup>3</sup>Department of Biomedical Engineering, Illinois Institute of Technology, Chicago, Illinois, USA

<sup>4</sup>Rush Alzheimer's Disease Center, Rush University Medical Center, Chicago, Illinois, USA

<sup>5</sup>San Francisco Veterans Affairs Health Care System

<sup>6</sup>Department of Ophthalmology, University of California at San Francisco (UCSF), San Francisco, California, USA

## Correspondence

Fanny Elahi, Weill Institute for Neurosciences, Department of Neurology, University of California at San Francisco (UCSF), 675 Nelson Rising Lane, Suite 190, San Francisco, CA, 94158, USA.

E-mail: [fanny.elahi@ucsf.edu](mailto:fanny.elahi@ucsf.edu)

## Abstract

**Introduction:** Development of novel diagnostic tools is a top research priority in vascular dementia. A major obstacle is the lack of a simple, non-invasive method to visualize cerebral arteriolar walls in vivo. Retinal arterioles offer a window into the cerebral circulation.

**Methods:** Intensity-based retinal arteriolar visualization in optical coherence tomography (I-BRAVO) was applied to evaluate mean wall thickness (MWT) and wall-to-lumen ratio (WLR) in 250 subjects with sporadic and genetic cerebral small vessel disease (CSVD), non-vascular neurodegenerative diseases (NVND), and healthy controls (HC) in association with imaging and cognitive markers.

**Results:** MWT and WLR were higher in CSVD, associated with severity of vascular white matter lesions, and correlated with magnetic resonance imaging-based intracranial arteriolosclerosis score. WLR correlated with gray and white matter volume and differentiated asymptomatic sporadic CSVD from HC (area under the curve = 0.82).

**Discussion:** I-BRAVO is a rapid, non-invasive tool. MWT and WLR were associated with imaging markers of CSVD and could contribute to early identification of sporadic CSVD.

## KEYWORDS

cerebral autosomal dominant arteriopathy with subcortical infarcts and leukoencephalopathy, cerebral small vessel disease, retinal vessels, vascular dementia, white matter disease

## 1 | INTRODUCTION

Cerebral vascular pathologies are pivotal contributors to neurodegenerative disease, stroke, and ultimately dementia, with tremendous

socioeconomic importance.<sup>1</sup> Vascular cognitive impairment (VCI) is the second most common form of dementia in the elderly.<sup>1</sup> Therefore, identifying vascular biomarkers and developing novel diagnostic tools to assess vascular pathology load accurately has become one of the top research priorities of the National Institutes of Health (NIH).<sup>2</sup> A significant obstacle to accurately appreciating the vascular contribution to cognitive impairment in dementia is the lack of a simple,

#Fanny M. Elahi and Ari J. Green contributed equally to this study.

This is an open access article under the terms of the [Creative Commons Attribution-NonCommercial](https://creativecommons.org/licenses/by-nc/4.0/) License, which permits use, distribution and reproduction in any medium, provided the original work is properly cited and is not used for commercial purposes.

© 2022 The Authors. *Alzheimer's & Dementia: Diagnosis, Assessment & Disease Monitoring* published by Wiley Periodicals, LLC on behalf of Alzheimer's Association.

## RESEARCH IN CONTEXT

- **Systematic Review:** We conducted a literature review in PubMed. There are numerous publications reporting the changes in different retinal vasculature structures in cerebral small vessel disease (CSVD). Yet, only one study evaluated the use of intensity-based measurements of retinal arteriolar metrics in CSVD and their association with cerebrospinal fluid parameters.
- **Interpretation:** Retinal arteriolar metrics correlate with neuroimaging measures of CSVD, neurodegenerative imaging markers, and with cognitive performance and showed high sensitivity and specificity discriminating asymptomatic sporadic and genetic CSVD from other dementia causes and healthy controls.
- **Future Directions:** This article demonstrates that non-invasive retinal arteriolar wall visualization is a rapid, non-expensive tool that reflects intracranial arteriolar pathology and holds the potential for application in early recognition of CSVD and as a possible dynamic treatment marker. The next steps should aim to provide a prospective, multicenter validation of the diagnostic and prognostic application of intensity-based retinal arteriolar visualization in optical coherence tomography in sporadic and genetic CSVD.

standardized method to visualize cerebral arterioles in vivo. Beyond that, the currently used neuroimaging biomarkers, such as white matter hyperintensities (WMH), lacunes, and microbleeds, are markers of irreversible tissue damage and cannot be considered surrogate, dynamic, treatment markers.<sup>3</sup> In addition, WMH are not specific, as they can also result from non-vascular etiologies in Alzheimer's disease (AD) and frontotemporal lobar degeneration (FTLD).<sup>4</sup> Researchers and clinicians often rely on these indirect neuroimaging measures despite the limited resolution of conventional computed tomography and magnetic resonance imaging (MRI) imaging because direct visualization of cerebral small vessels (CSV) is not feasible.<sup>5</sup>

Investigating the retinal vasculature offers a unique window into the cerebral vascular bed.<sup>6</sup> A large body of evidence supports retinal macro- and microvascular alterations in vascular and non-vascular dementias.<sup>7</sup> Nevertheless, previous funduscopy-based methods quantify mainly traditional markers of retinopathy (arteriovenous nicking, vascular caliber changes, and vascular attenuation) and lack the direct visualization of the in vivo transparent arteriolar vessel wall, which might hamper the accurate quantification of retinal arteriolar changes. Similarly, high-resolution optical coherence tomography angiography (OCT-A) demonstrates the lumen structure without sufficient demonstration of the vascular wall. In addition, many of the previous studies had small samples of VCI participants and were not sufficiently powered to analyze retinal vessel parameters.<sup>7</sup> To date, the biological

concept of parallel changes in the retinal arterioles and their cerebral counterparts in cerebral small vessel disease (CSVD) has never been validated in vivo, as the visualization of the CSV is not feasible.

Intensity-based retinal arteriolar visualization in OCT is a novel, rapid, non-invasive method of visualization of the retinal arteriolar structure.<sup>8-10</sup> The method, referred to in this work as I-bRAVO, leverages the high axial resolution and standardized quantification OCT ring scan diameters, which allow a rapid (less than 5 minute per patient) assessment of mean wall thickness (MWT), lumen diameter (LD), and wall-to-lumen ratio (WLR) with high intra- and inter-rater reliability.<sup>8</sup> One previous pilot study reported increased MWT and WLR of the temporal retinal arterioles in a small number of participants with CSVD compared to healthy controls (HC), including healthy elderlies.<sup>10</sup> In this study, retinal arteriolar parameters were quantified using I-bRAVO in a large cross-sectional cohort, including various clinical phenotypes of neurodegenerative diseases. We aimed to evaluate the correlation between retinal arteriole parameters and a novel imaging classifier for arteriosclerosis.<sup>11</sup> In addition, we analyzed the association of retinal vascular measurements with WMH of vascular origin, imaging markers of neurodegeneration (gray and white matter atrophy), and cognition.

## 2 | METHODS

### 2.1 | Study population

OCT scans were retrospectively identified between August 1, 2020 and December 1, 2020 from participants who were enrolled in ongoing longitudinal studies (since 2012) of brain aging and neurodegenerative disease at the Memory and Aging Center at University of California San Francisco (UCSF; federally funded studies: Aging and Cognition, Chronic Inflammation, MarkVCID studies, and Alzheimer's Disease Research Center, VascBrain; and Larry L. Hillblom foundation Aging Network study). All study participants underwent physical examination, identification of cardiovascular disease risk factors (blood pressure, body mass index, history of hyperlipidemia, hypertension, smoking, and diabetes), extensive neuropsychological testing, and MRI. Classification as HC, clinically asymptomatic (cognitively, behaviorally, and functionally) participants with evidence of vascular MRI lesions (aCSVD), and cognitive impairment due to AD, VCI, FTLD, primary progressive aphasia (PPA), and sporadic Creutzfeldt-Jakob disease (sCJD) was made through a multidisciplinary consensus conference based on clinical history and available neuroimaging, biomarkers, and family history. In aCSVD and VCI, the white matter lesions were considered of vascular origin by board-certified neuroradiologists, and when other causes of similar imaging findings (such as inflammatory or metabolic diseases) were excluded by the treating board-certified neurologists. All participants diagnosed with cerebral autosomal dominant arteriopathy with subcortical infarcts and leukoencephalopathy (CADASIL), either symptomatic or asymptomatic, had a pathological mutation in neurogenic locus notch homologue protein 3 gene (*NOTCH3*).<sup>12</sup> Familial CJD (fCJD) cases were diagnosed after the detection of pathological mutations in the human prion protein (*PRNP*) gene. Exclusion

criteria were active or uncontrolled psychiatric diseases such as psychosis, brain tumor, or history of brain surgery. In addition, participants with clinically significant ophthalmological abnormalities, such as glaucoma, vision-compromising cataract, macular degeneration, or cystoid macular edema, based on ophthalmological evaluation (AG) were not included.

## 2.2 | Ethical approval

All study participants provided informed consent, and the study protocol was approved by the UCSF Human Research Protection Program and Institutional Review Board (11-05333). The research was performed in accordance with the code of ethics of the World Health Organization.

## 2.3 | OCT examination and assessment of the retinal arterioles

A detailed description of the intensity-based assessment of retinal vessels is described elsewhere.<sup>8-10</sup> In summary: OCT examination was performed using spectral-domain (SD)-OCT (Spectralis platform, Heidelberg Engineering; software version 6.12). Retinal vessels were visualized using a 3.4 mm circular scan around the optic nerve. All included scans fulfill the OSCAR-IB criteria.<sup>13</sup> Of special relevance were "O": obvious problems, "S" signal strength >15, "C" all scans were appropriately centered, "R," scans with obvious retinal pathology were excluded, "I" optic nerve head was well illuminated, "B" illumination beam placed correctly. The "A" was not relevant for our findings, as our analysis does not involve segmentation algorithm. The median Automatic Real Time (ART) function and signal index quality were exported for each of the included ring scans. Signal quality between 20 and 25 is considered good and above 25 excellent.<sup>14</sup>

We analyzed the superior temporal arteriole of the central retinal artery at its crossing on the 12° circular scan using intensity-based analysis. Inner wall thickness (IWT), outer wall thickness (OWT), and LD were assessed in both eyes.<sup>8,9</sup> To increase the accuracy of the outer wall measurements, in each individual scan, the intensity-based curve's end was placed to match the outer rim of the outer wall structure as visualized on the B-scan (Figure 1). The MWT was the mean of the IWT and OWT values. The WLR, as a composite measure of the vessel pathology, was calculated by dividing the MWT of the included retinal arterioles by the corresponding LD; in the case of bifurcation of the superior retinal arteriole or arteriovenous crossing at the ring scan, the inferior temporal arteriole was assessed instead, as prior studies did not show any significant difference in the vessel parameters of the superior and inferior temporal branches.<sup>9</sup> All steps of data acquisition were conducted by individuals who were blinded to the working hypothesis and group assignment. Retinal vessel parameters were measured by two raters blinded to the underlying diagnosis, imaging findings, and cardiovascular risk factor evaluation. Inter-rater reliability is demonstrated in Figure S1 in supporting information.

## 2.4 | Magnetic resonance imaging

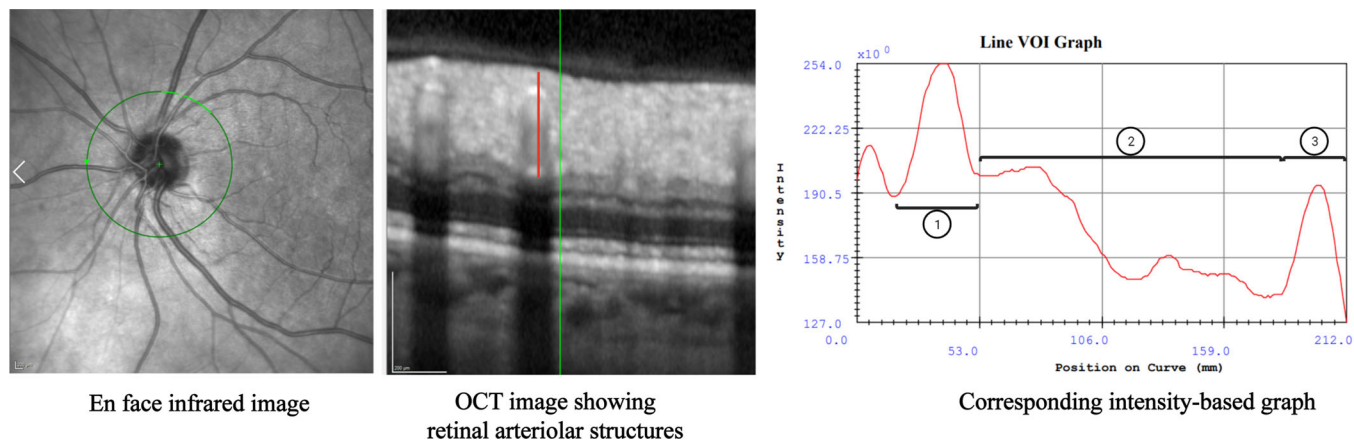
Magnetization-prepared rapid gradient echo (MPRAGE) sequences were used to acquire T1-weighted images with the following parameters: sagittal slice orientation; slice thickness = 1.0 mm; slices per slab = 160; in-plane resolution = 1.0 × 1.0 mm; matrix = 240 × 256; TR = 2300; TE = 2.9; TI = 900 ms; flip angle = 9°. Fluid attenuated inversion recovery (FLAIR) magnetic resonance images were acquired using the following parameters: slice thickness = 1.00 mm; slices per slab = 176; in-plane resolution = 1.0 × 1.0 mm; matrix = 256 × 256; TR = 5000; TE = 397; TI = 1800 ms; flip angle = 120°. FLAIR images were used to evaluate the Fazekas scores of superficial and deep white matter changes.<sup>15</sup> Tissue segmentation of the T1-weighted images was performed using SPM12 (Wellcome Trust Center for Neuroimaging, <http://www.fil.ion.ucl.ac.uk/spm>) unified segmentation. Diffusion tensor imaging (DTI) protocol used the following parameters: 15 non-collinear gradient directions with b = 1000 s/mm<sup>2</sup>, one b = 0 reference image, 35 contiguous slices of 3 mm thickness, TR/TE = 12,400/69 ms, 128 × 128 matrix covering a field of view of 25.6 × 25.6 interpolated to give a final 1 × 1 × 3 mm<sup>3</sup> resolution). Total gray matter and white matter were calculated by multiplying each participant's unsmoothed and unwarped probability maps by the voxel size in the respective tissues.<sup>16</sup> The Fazekas score was estimated by board-certified neuroradiologists.

## 2.5 | ARTerioloSclerosis classifier

ARTerioloSclerosis (ARTS) is a novel, validated MRI-based classifier of arteriolosclerosis trained by applying machine learning on MRI and neuropathology data from the same older adults. A detailed description of ARTS can be found elsewhere.<sup>17</sup> In summary, ARTS predicts the presence of moderate to severe arteriolosclerosis based on MRI measures of WMH, diffusion fractional anisotropy, and demographic features (age, sex, and education). The higher the ARTS score, the higher the likelihood of arteriolosclerosis. The score was calculated in a subgroup of the participants using the Rush-IIT ARTS biomarker kit (version 1.0), when all the required MRI sequences were available.

## 2.6 | Cognitive testing

Neuropsychological test scores from the National Alzheimer's Coordinating Center Uniform Data Set (UDS v3.0) were used to calculate an executive function composite score (UDS3-EF), as previously described.<sup>18</sup> The UDS3-EF is an item response theory-based composite of executive functioning and processing speed derived from seven UDS3-EF test scores: number span backward (total correct trials), Trail Making Test parts A and B (correct lines per minute), lexical fluency (F and L words; total correct), and category fluency (animals and vegetables; total correct). For this study, we used the demographically adjusted standardized (z) UDS-EF score, which applies a nonlinear



**FIGURE 1** Superior temporal branch of the retinal artery was identified at its crossing on the 12° circular scan (left). Intensity-based graph (right) was generated using the volume of interest (VOI) line (middle figure, red line). Dimensions of inner wall (1), lumen (2), and outer wall (3) were calculated and corrected to the optical coherence tomography (OCT) image scale

adjustment for age and linear adjustments for sex and education.<sup>18,19</sup> Higher scores indicate better executive functioning.

## 2.7 | Statistical analysis

Appropriate summary statistics were applied to describe the different variables, that is, mean with standard deviation or median with interquartile range for continuous variables and frequencies (percentages) for categorical variables. Pearson ( $r$ ) or nonparametric Spearman's ( $\rho$ ) correlation coefficients were used to test the correlations between various parameters. All regression analyses were performed using multivariate linear mixed-effect models with participant-ID as random effect (to adjust for repeated measures [eyes] per subject), and the models were fitted using maximum likelihood estimation. Logarithmic transformation ( $\log$ ) was performed for skewed variables. Sex, age, and the retinal arteriolar parameter of interest were evaluated as fixed effects. The standardized estimated effect size of the included retinal parameters was reported as Cohen's  $f^2$ .  $f^2 \geq 0.02$ ,  $f^2 \geq 0.15$ , and  $f^2 \geq 0.35$  represent small, medium, and large effect sizes, respectively.<sup>20</sup> As the most prominent vessel changes were expected in two groups with completely different age spectra in our cohort (CADASIL and VCI), correction for age was omitted when investigating group differences. Due to the small number of symptomatic participants with *NOTCH3* or *PRNP* mutations, they were analyzed collectively with asymptomatic participants in the CADASIL or *PRNP* groups, respectively. Receiver operating characteristic (ROC) curves were calculated to estimate the discriminative ability of the included retinal vessels between the different clinical subgroups. The cut-off values and corresponding sensitivity and specificity were selected based on the Youden index. Statistical significance was set at  $P < .05$ . All included group comparisons were corrected for multiple testing using Bonferroni's procedure. Statistical analysis was performed using IBM SPSS software version 25 and RStudio (version 3.6.3), including the following packages: lme4 (version 1.1–26) and effect size (version 0.4.3).

## 3 | RESULTS

### 3.1 | Study population

In this study, we assessed 500 eyes from 250 participants. The median ring scans ART and signal quality were 100 (interquartile range [IQR] 100 to 100) and 31 (IQR: 28 to 33), respectively. A total of 112 (44.8%) research participants had CSVD. Of these, 41 (16.4% of total population) had sporadic VCI, 21 (8.4%) had *NOTCH3* mutations causing CADASIL, and 50 (20%) had aCSVD. Of the participants with *NOTCH3* mutations, 16 were asymptomatic (no vascular events, cognitive abnormalities, or migraine). An additional 112 participants with non-vascular neurodegenerative diseases (NVND) comprised 44.8% of the cohort. This group included 42 (16.8%) participants with AD, 21 (8.4%) with behavioral variant frontotemporal dementia (bvFTD), 14 (5.6%) with PPA, 15 (6.0%) with sCJD, and 20 (8.0%) *PRNP* mutation carriers (all asymptomatic except three participants). In addition, 26 healthy participants (HC) without cognitive impairment or vascular MRI lesions were included (10.4%). The demographic characteristics, retinal arteriolar parameters, and cognitive performance of the included individuals are summarized in Tables 1 and 2. WLR showed a statistically significant but weak correlation with age ( $\rho = .14$ ,  $P = .03$ ). Females had higher MWT (27.6 vs. 26.8  $\mu\text{m}$ ,  $P = .03$ ,  $f^2 = 0.02$ ) and WLR (0.30 vs. 0.28,  $P = .02$ ,  $f^2 = 0.02$ ) than males.

### 3.2 | Retinal vessel parameters are associated with the extent of cerebral arteriolosclerosis

Higher MWT and WLR were associated with higher ARTS scores ( $\rho = .46$ ,  $.49$ , respectively;  $P < .001$ ,  $n = 65$ ). The correlation remained significant after correcting for age and sex for both MWT and WLR (unstandardized beta [B] = 0.1 and 6.7, 95% confidence interval [CI] [0.05 to 0.14] and [4.06 to 9.34],  $f^2 = 0.3$  and 0.31, respectively,  $P < .001$

**TABLE 1** Demographics, retinal arteriole parameters, and cognitive metrics of the included participants

| Variable  | Cerebral small vessel disease (CSVD)<br>n = 112 (44.8%) | Non-vascular neurodegenerative diseases (NVND)<br>n = 112 (44.8%) | Healthy controls (HC)<br>n = 26 (10.4%) | P-values* |
|---|---|---|---|-----------|
| Median age (IQR)  | 72 (55–80)  | 64 (54–72)  | 38 (33–46)                              | <.001     |
| Sex (male/female)   | 51/61   | 56/56   | 13/13                                   | .781      |
| Education (in years)  | 17 (16–19)  | 16 (16–18)  | 16 (15–16)                              | .005      |
| Evidence of any cardiovascular risk factors (CVRF)                    | 64/112 (57.1%)  | 44/112 (39.3%)  | 3/26 (11.5%)                            | <.001     |
| Mean wall thickness (± SD)  | 28.18 (± 4.07)  | 26.72 (± 3.39)  | 25.22 (± 3.19)                          | <.001     |
| Mean lumen diameter (± SD)  | 93.92 (± 11.36)   | 92.66 (± 11.83)   | 102.93 (± 9.73)                         | <.036     |
| Mean wall-to-lumen ratio (± SD)                                       | 0.30 (± 0.06)   | 0.29 (± 0.05)   | 0.25 (± 0.04)                           | <.001     |
| Median Mini-Mental State Examination (MMSE) (IQR), No. (% with data)  | 29 (28–30), 95 (84.8%)                                  | 25 (22–28), 108 (96.4%)   | 30 (29–30), 22 (84.6%)                  | <.001     |
| Adjusted Uniform Data Set (v3.0) executive function (UDS3-EF) z-score | -0.29 (± 1.13)  | -2.09 (± 1.49)  | -0.01 (± 0.78)                          | <.001     |

\*P-values from chi-square test for sex and CVRF and Kruskal-Wallis H test for the remaining variables  
Abbreviations: IQR, interquartile range; SD, standard deviation.

**TABLE 2** Retinal vessel metrics in each of the study subpopulation

|                                 | Cerebral small vessel disease (CSVD) |                 |               | Non-vascular neurodegenerative diseases (NVND) |              |               |               |               | Healthy controls |
|---------------------------------|--------------------------------------|-----------------|---------------|--|--------------|---------------|---------------|---------------|------------------|
|                                 | VCI                                  | NOTCH3 mutation | aCSVD         | AD   | bvFTLD       | PPA           | sCJD          | PRNP mutation |                  |
| # or eyes                       | 82                                   | 42              | 100           | 84   | 42           | 28            | 30            | 40            | 52               |
| Mean wall thickness (± SD)      | 27.47 (3.64)                         | 32.4 (3.7)      | 26.97 (3.38)  | 27.03 (3.27)                                   | 27.34 (3.47) | 26.49 (2.95)  | 27.02 (3.61)  | 25.38 (3.48)  | 25.22 (3.19)     |
| Mean lumen diameter (± SD)      | 93.46 (11.76)                        | 93.4 (10.7)     | 94.54 (11.37) | 93.78 (11.23)                                  | 93.11 (9.21) | 96.33 (13.34) | 89.14 (14.53) | 89.92 (11.50) | 102.93 (9.73)    |
| Mean wall-to-lumen ratio (± SD) | 0.30 (0.05)                          | 0.35 (0.06)     | 0.29 (0.05)   | 0.29 (0.05)                                    | 0.30 (0.05)  | 0.28 (0.05)   | 0.31 (0.06)   | 0.29 (0.05)   | 0.25 (0.04)      |

Abbreviations: aCSVD, asymptomatic cerebral small vessel disease; AD, Alzheimer's disease; bvFTLD, behavioral variant frontotemporal lobar degeneration; NOTCH3, neurogenic locus notch homologue protein 3 gene; PPA, primary progressive aphasia; PRNP, human prion protein gene; sCJD, sporadic Creutzfeldt-Jakob disease; SD, standard deviation; VCI, vascular cognitive impairment.

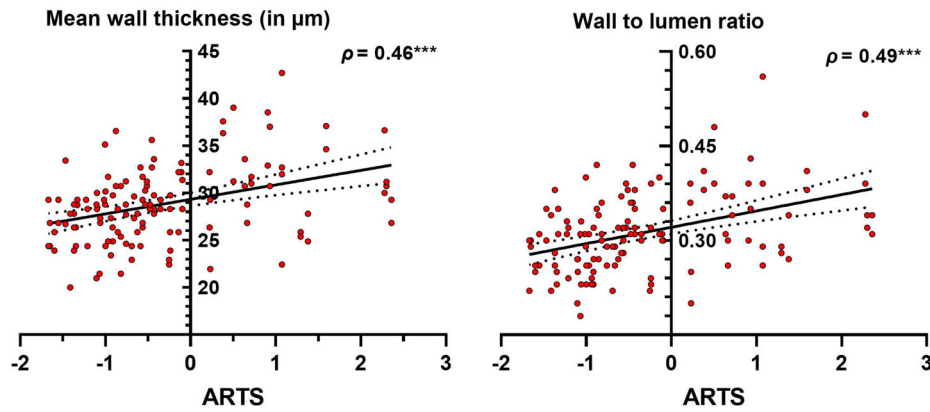
for both; Figure 2). No correlation was found between age and ARTS score.

### 3.3 | Retinal arteriolar parameters in the study population

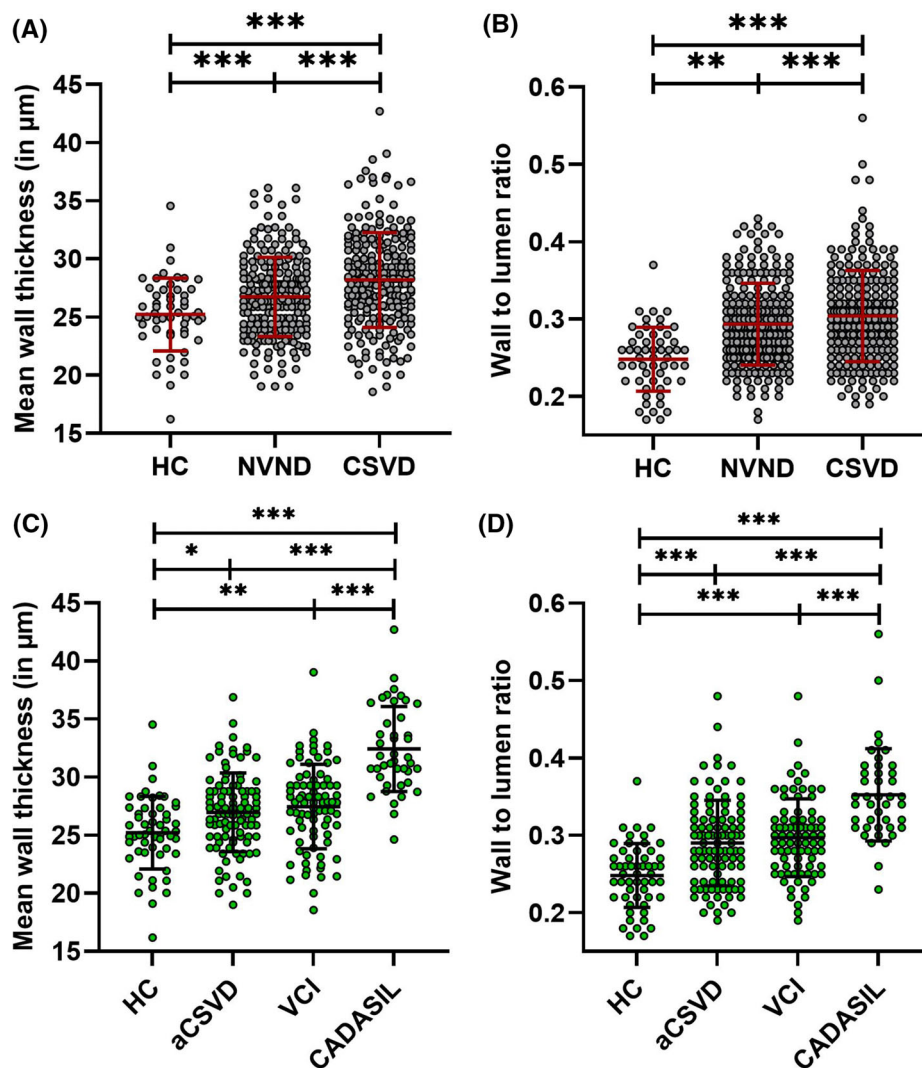
Participants with CSVD had higher MWT compared to those with NVND and HC (B = 1.71 [0.89 to 2.53], 3.22 [1.89 to 4.54],  $f^2 = 0.05$  and 0.12,  $P < .001$  for both). Similarly, participants with CSVD had higher WLR (B = 0.014 [0.002 to 0.03], 0.06 [0.04 to 0.08],  $f^2 = 0.02$ , and 0.2,

$P = .014$  and  $<.001$ , respectively) compared to those with NVND and HC, respectively. Lumen diameter did not differ significantly between CSVD and NVND but differed compared to HC (B = -8.96 [-13.17 to -4.75],  $f^2 = 0.11$ ,  $P < .001$ ; Table 1, Table 2, and Figure 3). Those results remained significant after correction for age (Table S1 in supporting information).

Based on the variability in arteriolar pathology between inherited and sporadic CSVD,<sup>21</sup> we compared the retinal arteriolar parameters between the CSVD subgroups. Participants with CADASIL had the most notable vessel changes compared to those with VCI and HC. MWT and WLR were higher in CADASIL (32.43  $\mu\text{m} \pm 3.66$ , 0.35  $\pm 0.06$ )



**FIGURE 2** Retinal arteriolar parameters in correlation with imaging classifier of intracranial arteriosclerosis (ARTS). ARTS correlated with mean wall thickness of retinal arterioles (left) and wall-to-lumen ratio (right) from 130 eyes. \*\*\*:  $P < .001$



**FIGURE 3** Differences in retinal arteriolar parameters between clinical subgroups. Mean wall thickness (MWT; A) and wall-to-lumen ratio (WLR; B) were higher in participants with sporadic, genetic, and asymptomatic cerebral small vessel disease (CSVD) compared to non-vascular dementias (NVND) and healthy controls (HC). Moreover, cerebral autosomal dominant arteriopathy with subcortical infarcts and leukoencephalopathy (CADASIL) participants showed the most prominent difference in MWT (C) and WLR (D) compared to other causes of vascular cognitive impairment (VCI), asymptomatic CSVD (aCSVD), and HC. \*:  $P < .05$ , \*\*:  $P < .01$ , \*\*\*:  $P < .001$

versus VCI ( $27.47 \mu\text{m} \pm 3.64$ ,  $0.30 \pm 0.05$ ;  $B = 4.58 [2.98 \text{ to } 6.16]$  and  $0.05 [0.03 \text{ to } 0.08]$ ,  $f^2 = 0.77$  and  $0.22$ , respectively,  $P < .001$  for both). Similarly, higher MWT and WLR were seen in VCI compared to HC ( $B = 2.38 [0.92 \text{ to } 3.85]$  and  $0.05 [0.03 \text{ to } 0.08]$ ,  $f^2 = 0.22$  and  $0.52$ ,  $P = .001$ , and  $<.001$ , respectively; Figure 2).

Considering the cumulative effect of cardiovascular risk factors on vessel wall morphology, we assessed the arteriolar parameters in our cases classified according to the presence or absence of cardiovascular risk factors. MWT and WLR were higher in CSVD ( $B = 1.64 [0.49 \text{ to } 2.81]$ ,  $0.02 [0.001 \text{ to } 0.04]$ ,  $f^2 = 0.03$ , and  $0.01$ ,  $P = .001$  and  $.037$ , respectively) compared to NVND with cardiovascular risk factors (mean  $26.93 \mu\text{m} \pm 3.43$  and  $0.29 \pm 0.05$ ). In addition, WLR was higher in NVND with cardiovascular risk factors than in HC ( $B = 0.04 [0.02 \text{ to } 0.07]$ ,  $f^2 = 0.31$ ,  $P < .001$ ). For MWT, the difference was not significant ( $P = .062$ ).

### 3.4 | Correlation with MRI biomarkers of vascular pathology

Higher MWT and WLR were associated with an increased burden of white matter changes of vascular origin (periventricular and deep MRI white matter lesions), as detailed in Table 3 and Figure 4. Moreover, higher WLR was associated with lower gray matter volume ( $\text{GM}_{\text{VOL}}$ ) in the entire study population ( $\rho = -.3$ ,  $P < .001$ ). In addition, a weak negative association ( $\rho = -.1$ ,  $P = .037$ ) was found between the MWT and  $\text{GM}_{\text{VOL}}$ . After correcting for age and sex, the negative correlation between  $\text{GM}_{\text{VOL}}$  and WLR remained significant ( $B = -142.75 [-250.74 \text{ to } -34.77]$ ),  $f^2 = 0.02$ ,  $P = .01$ ). The association was stronger by fitting additional slopes for clinical diagnosis (CVSD vs. NVND vs. HC;  $B = -163.18 [-273.43 \text{ to } -52.74]$ ),  $f^2 = 0.02$ ,  $P = .004$ ). A similar association between WLR and  $\text{GM}_{\text{VOL}}$  was found in cases with sporadic CSVD ( $B = -207.88 [-380.5 \text{ to } -35.3]$ ,  $f^2 = 0.05$ ,  $P = .019$ ), but not in CADASIL participants. In addition, we found a negative correlation ( $\rho = -.3$ ,  $P = .005$ ) between WLR and white matter volume ( $B = -165.84 [-310.07 \text{ to } -21.62]$ ,  $f^2 = 0.04$ ,  $P = .024$ ).

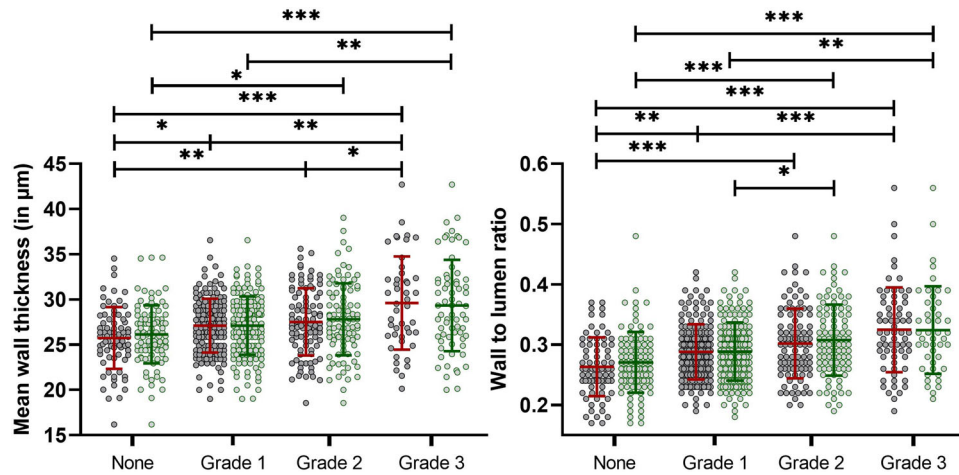
### 3.5 | Discriminative potentials of retinal arteriole parameters

MWT and WLR could differentiate participants with CADASIL from all other included clinical subgroups (aCSVD, VCI, NVND, and HC; area under the curve [AUC] =  $0.92 [0.86 \text{ to } 0.98]$  and  $0.85 [0.77 \text{ to } 0.92]$ , respectively,  $P < .001$ ). A cut-off value of  $30.95 \mu\text{m}$  (MWT) and  $0.32$  (WLR) identified participants with CADASIL with 93% and 79% specificity and 81% and 86% sensitivity, respectively. In cognitively normal participants (normal cognitive screening tests), the average WLR of both eyes could differentiate between participants with asymptomatic vascular MRI lesions and HC (AUC =  $0.82 [0.72 \text{ to } 0.91]$ ,  $P < .001$ ). In this group, a WLR cut-off value of  $0.275$  recognized participants who had asymptomatic vascular MRI changes with a specificity of 89% and sensitivity of 67%.

**TABLE 3** Association between white matter changes and retinal arteriolar metrics

| Fazekas classification (n)                   | Mean wall thickness in $\mu\text{m}$ (SD) |  |                   | Mean wall-to-lumen ratio                 |  |             |
|--|---|--|-------------------|--|--|-------------|
|  | Participants with detectable MRI lesions  | Participants without detectable lesions  | Cohen $f^2$       | Participants with detectable MRI lesions | Participants without detectable lesions  | Cohen $f^2$ |
| Periventricular white matter lesion severity |   |  |                   |  |  |             |
| Pencil thin (84)                             | $27.11 (\pm 2.98)$                        | $25.75 (\pm 3.41)$                       | $0.16$            | $0.29 (\pm 0.05)$                        | $0.26 (\pm 0.05)$                        | $0.09$      |
| Smooth halo (47)                             | $27.52 (\pm 3.71)$                        |  | $0.08$            | $0.30 (\pm 0.06)$                        |  | $0.17$      |
| Irregular (34)                               | $29.33 (\pm 5.05)$                        |  | $0.22$            | $0.32 (\pm 0.07)$                        |  | $0.34$      |
| Deep white matter lesion severity            |   |  |                   |  |  |             |
| Punctate foci (83)                           | $27.11 (\pm 3.22)$                        | $26.14 (\pm 3.22)$                       | $0.03$            | $0.29 (\pm 0.05)$                        | $0.27 (\pm 0.05)$                        | $0.04$      |
| Early confluent (48)                         | $27.81 (\pm 3.98)$                        |  | $0.07$            | $0.31 (\pm 0.06)$                        |  | $0.14$      |
| Large confluent (23)                         | $29.61 (\pm 5.16)$                        | $3.02 [1.31 \text{ to } 4.73]$ , $<.001$ | $0.32 (\pm 0.07)$ |  | $0.05 [0.02 \text{ to } 0.08]$ , $<.001$ | $0.22$      |
|  |   | $0.19$                                   |                   |  |  |             |

Abbreviations: CI, confidence interval; SD, standard deviation.



**FIGURE 4** Retinal arteriolar parameters in association with the white matter lesion severity. Increasing mean wall thickness and wall-to-lumen ratio are associated with higher load of periventricular and deep white matter lesion load in magnetic resonance imaging. Green lines: deep white matter, red lines: periventricular white matter. \*:  $P < .05$ , \*\*:  $P < .01$ , \*\*\*:  $P < .001$

### 3.6 | Correlation between vascular parameters and cognitive performance

Finally, we evaluated the correlation between retinal arteriolar parameters and cognition, specifically executive function. The median duration between OCT and cognitive testing was 0 days [IQR 0 to 0]. Correcting for age, sex, and education, and fitting additional slopes for clinical diagnosis, we found no significant association between MMSE scores and MWT or WLR in the whole study population, CSVD, or VCI. Surprisingly, higher MWT was associated with a higher adjusted UDS-EF score in the CADASIL group ( $B = 0.13$  [0.03 to 0.23],  $f^2 = 0.37$ ,  $P = .01$ ).

## 4 | DISCUSSION

We describe a rapid, reliable, and inexpensive technique for assessing retinal arterioles as a surrogate marker for intracranial vascular pathology and as a tool for the early recognition of asymptomatic CSVD. The reported association between the novel ARTS classifier and retinal arteriolar parameters provides a long-awaited, first-in-kind, in vivo proof-of-concept for non-invasive retinal vessel imaging as a tool to visualize the cerebral vascular pathologies. Furthermore, we report increased MWT and WLR of the retinal arterioles in participants with sporadic and genetic CSVD compared to NVND and HC. In line with these findings, greater MWT and WLR correlated with imaging evidence of more significant vascular white matter lesion burden in CSVD and lower white matter volume in VCI. *NOTCH3* mutation carriers showed more prominent abnormalities than those with sporadic VCI, even in the asymptomatic stage of disease. These results are in strong agreement with the reported pathological changes found in the cerebral arterioles of participants with CSVD, showing more florid vessel changes CADASIL compared to that of sporadic VCI cases.<sup>21</sup> In addition, MWT and WLR showed promising applications in differen-

tiating CADASIL cases from other etiologies of cognitive impairment and HC with high sensitivity and specificity. Of note, CADASIL is a rare condition, and its diagnosis requires high clinical suspicion.

Nevertheless, recent investigations have stated that *NOTCH3* variants are much more common than previously assumed (1 in 450) and are associated with various cerebral vascular events.<sup>22</sup> Therefore, retinal parameters could potentially be used as a convenient and inexpensive tool to raise clinical suspicion of pathological *NOTCH3* mutations, thus facilitating early directed genetic testing. Among participants with CADASIL in our cohort, retinal arteriolar parameters were not associated with brain volume. This may be a result of the low mean age of the CADASIL group and changes in retinal parameters before detectable brain volume loss. Despite this, our findings support the promising utility of retinal arteriole assessment to better understand the vascular pathophysiology of CADASIL and warrant future study as a possible dynamic treatment response marker.

Regarding cognition, processing speed and executive function tests are more sensitive in reflecting longitudinal changes than memory and language tests in CSVD.<sup>23</sup> In our study, we found an initially counterintuitive positive correlation between MWT and UDS3-EF in participants with CADASIL. The clinical characteristics of our study population could provide clues for the unclear association between retinal vessels and cognition. The entire CSVD group performed better on average than participants with NVND, likely due in part to including both symptomatic and asymptomatic CSVD participants. In addition, several features of the CADASIL group may explain these seemingly discrepant findings: the CADASIL sample was relatively small, the participants were young, and the group contained many presymptomatic individuals. The different compositions of the VCI and CADASIL cohorts might explain the different patterns of correlations between retinal arteriolar metrics and executive function, and further studies in larger cohorts are warranted.

Early initiation of neurodegenerative disease treatments, even in the asymptomatic phase, might be more advantageous than



waiting until participants have already reached dementia levels of impairment.<sup>24</sup> With the introduction of specific preventive measures and treatments for VCI in the future, early recognition of asymptomatic stages would be a key step in its successful management. The high specificity of WLR for differentiating cognitively healthy individuals with vascular white matter lesions from those without suggests the potential utility of WLR as a preclinical biomarker in adults at high risk of developing cognitive impairments such as VCI due to CSVD. Bearing in mind that this technique is rapid and non-invasive, elderly individuals with risk factors might benefit from routine WLR assessment to identify those who may need further evaluation via brain MRI and possibly optimize the status of risk factors or initiate preventive treatment.

It should be noted that the population included in this study may not be entirely representative of the full spectrum of vascular-mediated cognitive impairment, as few of the included participants suffered from severe cognitive deterioration. In addition, more than half of the participants with NVND had MRI evidence of vascular white matter disease. Obtaining two “pure” groups with VCI and NVND is quite challenging in the clinical setting, given the high rates of comorbid vascular disease along the neurodegenerative disease spectrum and the variable contributions of vascular changes to observed cognitive and behavioral symptoms.

The vessel dimensions reported are in line with previous reports applying the intensity-based analysis. Indeed, MWT in HC was reported to be 23.9 and 24  $\mu\text{m}$ , while WLR was estimated to be 0.25 and 0.24.<sup>8,10</sup> Both parameters are very close to the findings from HC in our population (25.2 and 0.24 for MWT and WLR, respectively). Similarly, for sporadic CSVD, MWT was estimated to be 28.9  $\mu\text{m}$  and WLR 0.32.<sup>10</sup> resembling the findings in this larger study population. The overlapping results could support the robustness of the method among different populations and OCT imaging protocols.

Nevertheless, one limitation of I-bRAVO is the variable angioarchitecture of the retinal vessels between subjects, which might cause variation at the orientation of retinal arterioles at the ring scan. Yet, including both the superior and inferior branch of the retinal arteriole, from both eyes, lessens the effects of those variations. In addition, the retinal angioarchitecture is not expected to vary majorly within the same subject over longitudinal assessments. Beyond that, I-bRAVO is principally dependent on axial resolution of the retinal imaging as the vessel travels primarily in planes that are perpendicular to the ring scan/B scan. Therefore, the superior axial resolution of OCT becomes critical for appropriate generation of the wall intensity-based graphs. On the other hand, a method that aims to demonstrate details of the wall structure and morphological changes in the wall would definitely benefit from an enhanced lateral resolution (e.g., adaptive optics scanning laser ophthalmoscopy).

In summary, our study highlights that I-bRAVO may be a useful technique for identifying participants with cerebral arteriosclerosis. The discriminative power between clinical phenotypes with and without CSVD, as well as its association with white matter vascular lesions and neurodegenerative processes, justify the exploration of I-bRAVO as a possible dynamic treatment marker. The large-scale clinical application

of retinal arteriole wall measurements might allow early identification of participants suffering from CADASIL and asymptomatic vascular white matter changes.

## ACKNOWLEDGMENTS

The OCT scans were collected from participants participating in studies supported by NIH/NIA R01-AG031189, R56-AG055619, P50-AG-023501, P30-AG062422, PO1-AG019724, the Hillblom Foundation, and the Michael J. Homer Family Fund. The authors would also like to acknowledge support from the Veterans Affairs funding to FME IK2CX002180.

## CONFLICTS OF INTEREST

The authors report no conflicts of interest related to this work. All authors report no disclosures related to this work.

## AUTHOR CONTRIBUTIONS

Conceptualization: Ahmed Abdelhak, Ari J. Green, and Fanny M. Elahi. Data collection: Ahmed Abdelhak, Shivany Condor Montes, Alexandra Saias, Adam M. Staffaroni, Isaac Solomon, Christian Cordano, Frederike Cosima Oertel, Breton Asken, and Corrina Fonseca. Data analysis, interpretation, and verification: Ahmed Abdelhak, Isaac Solomon, Christian Cordano, Breton Asken, Adam M. Staffaroni, Adam M. Staffaroni, Michael Geschwind, Bruce L. Miller, Joel H. Kramer, Fanny M. Elahi, and Ari J. Green. Supervision: Ari J. Green and Fanny M. Elahi. Drafting, writing and revising the manuscript: all authors.

## ORCID

Ahmed Abdelhak  <https://orcid.org/0000-0001-9731-4169>

## REFERENCES

- Dichgans M, Leys D. Vascular cognitive impairment. *Circ Res*. 2017;120(3):573-591.
- Corriveau A, Koroshetz WJ, Gladman JT, et al. Alzheimer's Disease-Related Dementias Summit 2016: National research priorities. *Neurology*. 2017;89(23):2381-2391.
- Zwanenburg JJM, van Osch MJP. Targeting cerebral small vessel disease with MRI. *Stroke*. 2017;48(11):3175-3182.
- Arfanakis K, Evia AM, Leurgans SE, et al. Neuropathologic correlates of white matter hyperintensities in a community-based cohort of older adults. *J Alzheimers Dis*. 2020;73(1):333-345.
- Benjamin P, Viessmann O, MacKinnon AD, Jezzard P, Markus HS. 7 Tesla MRI in cerebral small vessel disease. *Int J Stroke*. 2015;10(5):659-664.
- Moss HE. Retinal vascular changes are a marker for cerebral vascular diseases. *Curr Neurol Neurosci Rep*. 2015;15(7):40.
- Dumitrascu OM, Qureshi TA. Retinal vascular imaging in vascular cognitive impairment: current and future perspectives. *J Exp Neurosci*. 2018;12:1179069518801291.
- Rim TH, Choi YS, Kim SS, et al. Retinal vessel structure measurement using spectral-domain optical coherence tomography. *Eye (Lond)*. 2016;30(1):111-119.
- Abdelhak A, Hubers A, Bohm K, Ludolph AC, Kassubek J, Pinkhardt EH. In vivo assessment of retinal vessel pathology in amyotrophic lateral sclerosis. *J Neurol*. 2018;265(4):949-953.
- Abdelhak A, Huss A, Brück A, et al. Optical coherence tomography-based assessment of retinal vascular pathology in cerebral small vessel disease. *Neurol Res Pract*. 2020;2(1):13.

11. Makkejad N, Evia AM, Tamhane AA, Bennett DA, Schneider JA, Arfanakis K. Cognitive decline prediction using an MRI-based classifier of arteriolar sclerosis and small vessel atherosclerosis. *Alzheimer's Dement*. 2020;16(S2).
12. Joutel A, Corpechot C, Ducros A, et al. Notch3 mutations in CADASIL, a hereditary adult-onset condition causing stroke and dementia. *Nature*. 1996;383(6602):707-710.
13. Schippling S, Balk LJ, Costello F, et al. Quality control for retinal OCT in multiple sclerosis: validation of the OSCAR-IB criteria. *Mult Scler*. 2015;21(2):163-170.
14. Gershoni A, Barayev E, Vainer I, et al. Thickness measurements taken with the spectralis OCT increase with decreasing signal strength. *BMC Ophthalmol*. 2022;22(1):148.
15. Fazekas F, Chawluk JB, Alavi A, Hurtig HI, Zimmerman RA. MR signal abnormalities at 1.5 T in Alzheimer's dementia and normal aging. *AJR Am J Roentgenol*. 1987;149(2):351-356.
16. Malone IB, Leung KK, Clegg S, et al. Accurate automatic estimation of total intracranial volume: a nuisance variable with less nuisance. *Neuroimage*. 2015;104:366-372.
17. Makkejad N, Evia AM, Tamhane AA, et al. ARTS: a novel in-vivo classifier of arteriolosclerosis for the older adult brain. *Neuroimage Clin*. 2021;31:102768.
18. Staffaroni AM, Asken BM, Casaletto KB, et al. Development and validation of the Uniform Data Set (v3.0) executive function composite score (UDS3-EF). *Alzheimers Dement*. 2020;17(4):574-583.
19. Kornak J, Fields J, Kremers W, et al. Nonlinear Z-score modeling for improved detection of cognitive abnormality. *Alzheimers Dement (Amst)*. 2019;11:797-808.
20. Selya AS, Rose JS, Dierker LC, Hedeker D, Mermelstein RJ. A practical guide to calculating Cohen's  $f(2)$ , a measure of local effect size, from PROC MIXED. *Front Psychol*. 2012;3:111.
21. Craggs LJ, Hagel C, Kuhlenbaeumer G, et al. Quantitative vascular pathology and phenotyping familial and sporadic cerebral small vessel diseases. *Brain Pathol*. 2013;23(5):547-557.
22. Cho BPH, Nannoni S, Harshfield EL, et al. NOTCH3 variants are more common than expected in the general population and associated with stroke and vascular dementia: an analysis of 200 000 participants. *J Neurol Neurosurg Psychiatry*. 2021;92(7):694-701.
23. Hamilton OKL, Backhouse EV, Janssen E, et al. Cognitive impairment in sporadic cerebral small vessel disease: a systematic review and meta-analysis. *Alzheimers Dement*. 2020;17(4):665-685.
24. Soejitno A, Tjan A, Purwata TE. Alzheimer's disease: lessons learned from amyloidocentric clinical trials. *CNS Drugs*. 2015;29(6):487-502.

## SUPPORTING INFORMATION

Additional supporting information can be found online in the Supporting Information section at the end of this article.

**How to cite this article:** Abdelhak A, Solomon I, Montes SC, et al. Retinal arteriolar parameters as a surrogate marker of intracranial vascular pathology. *Alzheimer's Dement*. 2022;14:e12338. <https://doi.org/10.1002/dad2.12338>